Acta Neurol Scand DOI: 10.1111/j.1600-0404.2008.01016.x

Copyright © 2008 The Authors
Journal compilation © 2008 Blackwell Munksgaard

ACTA NEUROLOGICA
SCANDINAVICA

Clinical spectrum and difficulties in management of hypothalamic hamartoma in a developing country

Papayannis CE, Consalvo D, Seifer G, Kauffman MA, Silva W, Kochen S. Clinical spectrum and difficulties in management of hypothalamic hamartoma in a developing country.
Acta Neurol Scand: DOI: 10.1111/j.1600-0404.2008.01016.x.
© 2008 The Authors Journal compilation © 2008 Blackwell Munksgaard.

Aim – We describe the clinical features, treatment and prognosis in a series of patients with epilepsy secondary to hypothalamic hamarthomas (HH) in a developing country. *Materials and methods* – Eight patients with epilepsy and HH were included between 1997 and 2006. We analyzed gender, age, age at seizure onset (ASO), seizure types (ST), mental retardation (MR), precocious puberty (PP), electroencephalogram (EEG)-magnetic resonance imaging (MRI) features and response to treatment. *Results* – Mean age 25.1 years, 2/6 female/male, none had PP, ASO 4.5 years. Complex partial seizure were the most frequent (100%), mean similar to those seen in temporal (62.5%) or frontal lobe epilepsy (37.5%). Exactly 87.5% developed gelastic seizures (GS). Half of the patients showed MR. Mild-to-severe MR was associated with the presence of multiple ST including atonic and complex partial seizures with frontal semiology. Interictal EEG was abnormal in 87.5% patients. Video EEG was performed in three cases with unspecific findings. HH were small and sessile in seven patients whereas large and pedunculated in one. All patients were refractory to medical treatment. In five, an additional procedure was performed without any significant improvement. *Conclusion* – These series show the heterogeneous spectrum of this entity and the difficulties in its treatment in a developing country.

C. E. Papayannis, D. Consalvo, G. Seifer, M. A. Kauffman, W. Silva, S. Kochen

Epilepsy Center, Department of Neurology, Ramos Mejía Hospital, Buenos Aires, Argentina

Key words: epilepsy; gelastic seizures; hypothalamic hamartomas; treatment options

Papayannis Cristina, Diaz Velez 3769 8°A, Buenos Aires 1200, Argentina
Tel.: 5411 49824276
Fax: 5411 49326101
e-mail: cpapayonis@intramed.net.ar

Accepted for publication February 20, 2008

Introduction

Hypothalamic hamartoma (HH) is a non-neoplastic lesion, with ectopically located tissue that resembles grey matter and contains neurons and glial cells in an anarchic organization (1). This lesion has proved to be intrinsically epileptogenic and the cause of the denominated 'diencephalic' epileptic seizures (1). Magnetic resonance imaging (MRI) is the method of choice in the diagnosis of this entity and it has delineated two types of HH, the pedunculated or parahypothalamic, and the sessile or intrahypothalamic (1–3). Although some authors have reported different manifestations in each type of HH, there is not a clear correlation between the imaging features of HH and its clinical presentation (4–6).

While it can be asymptomatic, it is usually associated with a specific syndrome characterized by pharmacoresistant epilepsy, severe behavior disorder, intellectual deterioration and precocious puberty (PP); each one of these symptoms can be found in different combinations and grades of severity. This syndrome has been called 'hypothalamic hamartoma with gelastic seizures' (HHGS) (1). GS consists of brief stereotyped attacks of meaningless laughter and is rarely associated with a pleasant feeling (7). Until the present time, the existence of a varied clinical spectrum has made it difficult to standardize treatment options for this pathology.

There are a small number of reports on HHGS in developing countries (3, 8). The main purpose of this study was to investigate the clinical

features, treatment and prognosis in our population.

Materials and methods

Eight patients with diagnosis of HHGS were evaluated at the epilepsy center, 'Ramos Mejía' Hospital, between 1997 and 2006. HH was diagnosed using a standardized 1.5 T MRI study that included T1- and T2-weighted, inversion recovery and fluid-attenuated inversion recovery acquisitions. We reviewed their clinical data: sex, age at seizure onset, seizure types according to International League against Epilepsy classification 1981 (9), neurological exam, presence of mental retardation, evidence of PP and response to treatment. Interictal electroencephalogram (EEG) recordings, video-EEG when available and MRI features were also evaluated. According to MRI, HH was defined as small if it was less than 1 cm in diameter and was classified as pedunculated/parahypothalamic (when it was attached to the hypothalamus by a stalk) or sessile/intrahypothalamic (with broad attachment to hypothalamus) (5, 10).

Results

Clinical and epidemiological data (Table 1)

Mean age of our population was 25.1 years (14–38 years), 2/6 female–male, they all have a negative family history of epilepsy or other neurological diseases and a normal neurological exam. Past medical history before epilepsy onset was relevant for two of eight patients (cases 6 and 8 had a history of perinatal anoxia). None of them had clinical or endocrinological signs of PP.

Types of seizures and epilepsy (Table 1)

Mean seizure onset age was 4.5 years (0.1–13 years). All patients presented more than one seizure type, with the exception of one patient that only had complex partial seizures. Complex partial seizures were the most frequent type of seizure in our population (they were present in all eight patients). These could be similar in semiology to those seen in temporal lobe epilepsy (cases 1, 2, 3, 6 and 8) or frontal lobe epilepsy (cases 4, 5 and 7). Other seizure types included generalized tonic-clonic seizures (six patients), atonic seizures (three patients), myoclonic (one patient), partial motor (one patient) and dacrystic seizures (one patient). All but one had GS. GS was the first seizure type in five of the eight patients. In case 2 the first seizure type was complex partial, in case 7 myoclonic and case 8 began with generalized tonic-clonic seizures.

Cognition and behavior (Table 1)

While all patients had normal developmental milestones previous to the beginning of epilepsy, half of the population developed an impairment of cognitive function later in the course of the disease. Only patients with mild-to-severe mental retardation (cases 4, 5 and 7) presented complex partial seizures with frontal semiology and atonic seizures. Two of them (4 and 5) showed generalized and multifocal features in EEG.

Interictal EEG (Table 2 and Fig. 1)

Interictal EEG showed different focal and generalized abnormalities in all patients except one that had a normal interictal EEG.

Video-EEG (Table 2 and Fig. 2)

Video-EEG was performed in only three patients. The ictal EEG showed diffuse attenuation of background activity without possibility of localizing or lateralizing seizure onset in one patient (case 1). In case 6, we observed left temporal ictal activity, and case 8 showed a diffuse fast rhythmic activity at seizure onset. In all patients, GS were brief and did not show any change in the EEG.

Table 1 Clinical features

Patients	1	2	3	4	5	6	7	8
Gender	F	M	M	M	M	M	M	F
Age (years)	33	20	26	19	14	21	30	38
Mental retardation	–	–	–	Mod	Sev	B	M	–
Age at seizure onset	3	13	5	2	2	3	0.1	8
First seizure type	Gel	CPS (T)	Gel	Gel	Gel	Gel	Myo	GTC
Seizure types	DS, CPS(T), GTC	–	CPS(T), GTC	CPS(F), A, GTC	CPS(F), GTC, A	CPS (T)	Gel, GTC, PMS, CPS(F), A	Gel, CPS(T)

F, female; M, male; Mod, moderate; Sev, severe; B, borderline; M, mild; Gel, gelastic seizure; CPS (T), complex partial seizure (temporal); CPS (F), complex partial seizure (frontal); Myo, myoclonic; GTC, generalized tonic clonic; DS, dacrystic seizure; A, atonic; PMS, partial motor seizure.

Table 2 Diagnostic methods and treatment

Patients	1	2	3	4	5	6	7	8
EEG interictal findings	SBA, right T S and PS	BT theta SW	BT S	2–2.5 HZ GSW and BT S	1–3 Hz GSW and BT S	Left O SW and BT-O S	SBA	N
Video-EEG ictal findings	DA	–	–	–	–	Left T	–	FRA
MRI: Large HH (>1 cm)	No	No	Yes	No	No	No	No	No
MRI: attachment	S	S	P	S	S	S	S	S
Additional treatment (AT)	–	–	–	L	L	CS, L	GK	L
Age at AT	–	–	–	12	15	15, 17	23	32

SBA, slowed background activity; S, spikes; PS, polyspikes; T, temporal; BT, bitemporal; SW, slow waves; GSW, generalized slow waves; O, occipital; DA, diffuse attenuation; FRA, fast rhythmic activity; S, sessile; P, pedunculated; L, LINAC; CS, conventional surgery; GK, gamma knife.

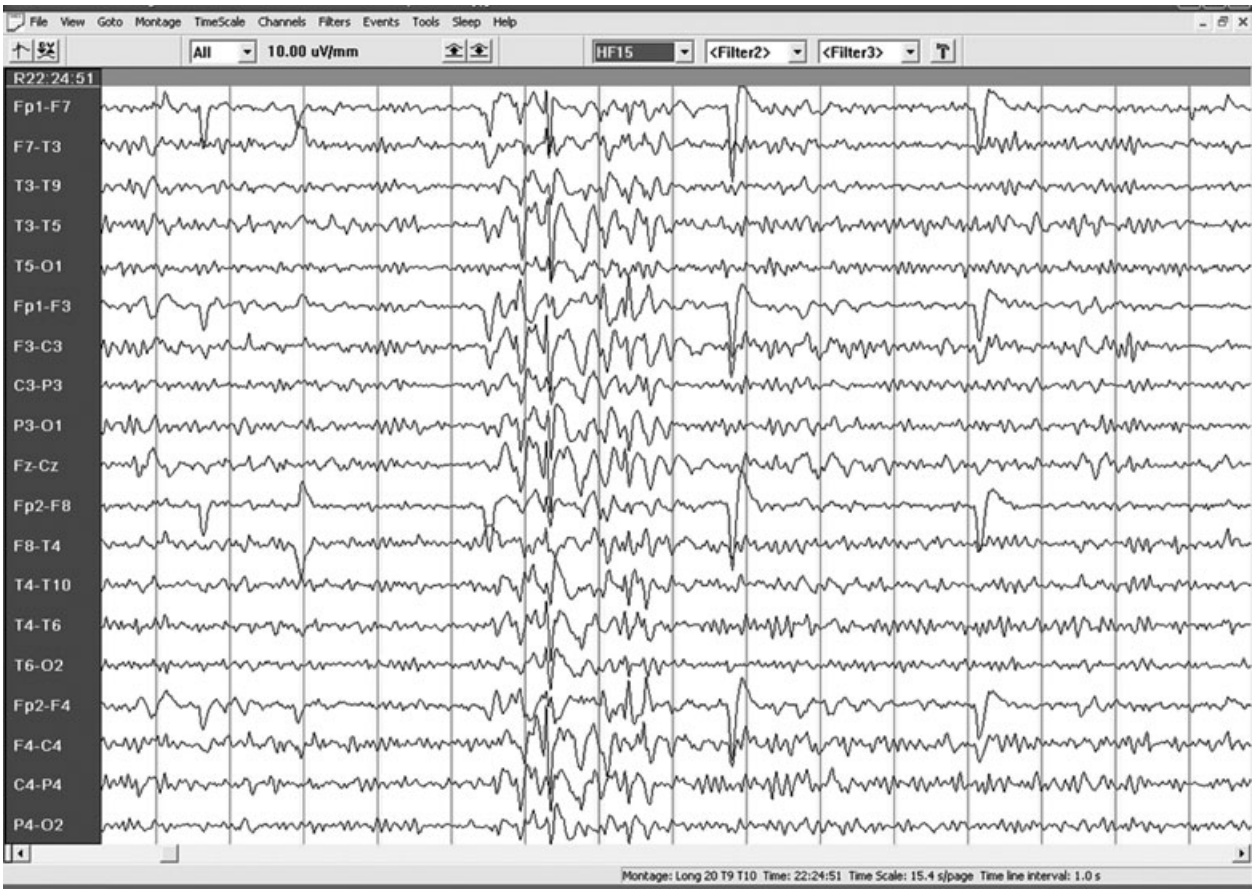

Figure 1. Interictal epileptiform abnormalities on scalp electroencephalogram showing 2–2.5 Hz, spike/polispike and slow wave activity, not accompanied by any clinical change (case 4).

MRI (Table 2, Figs 3 and 4)

Seven patients had small and sessile HH and only one patient had a large HH with a pedunculated attachment.

Treatment (Table 2)

All patients had received anti-epileptic drugs (AED) in monotherapy or polytherapy with 'classic' (phenytoin, phenobarbital, carbamazepine and valproic acid) and 'new' (lamotrigine, topiramate, levetiracetam, oxcarbazepine, felbamate and vigabatrine) drugs without an adequate control of seizures. Five patients underwent an additional procedure. Mean age at additional procedure was 19 years (12–32 years) with a mean duration of epilepsy (MDE) of 16 years (10–24 years). Four received linear accelerator (LINAC)-based radiosurgery, at doses between 1200 and 1800 Gy, one patient gamma knife (GK) and one underwent conventional surgery (CS). Case 6 underwent two

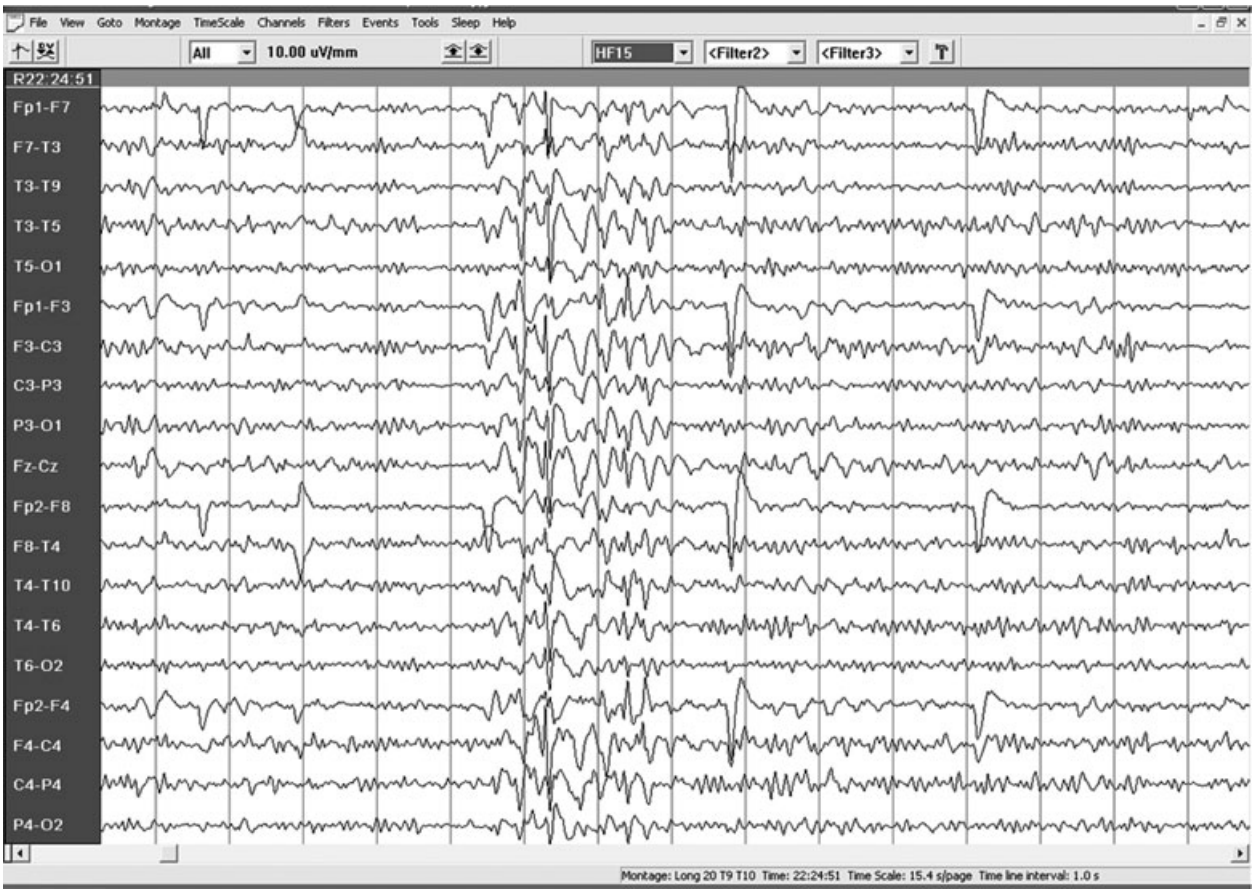

Figure 2. Scalp video-electroencephalogram telemetry showing ictal onset with a diffuse rhythmic fast activity pattern (case 8).

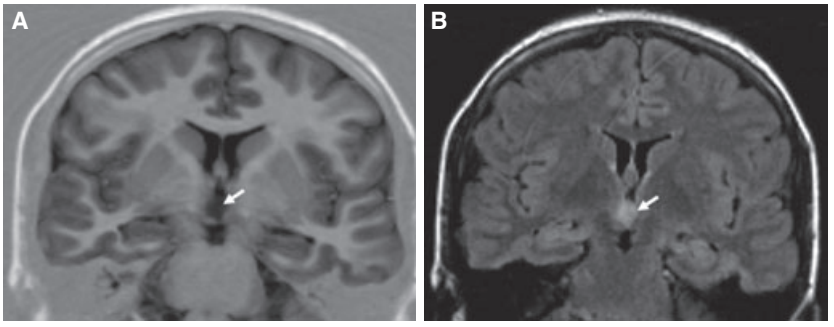

Figure 3. Small and sessile hypothalamic hamarthoma corresponding to case 2: (A) coronal inversion recovery sequence and (B) coronal fluid-attenuated inversion recovery sequence.

additional procedures. None of the patients showed side effects related to additional procedures.

- Case 4 underwent LINAC-based radiosurgery in 1999 at the age of 12 (MDE 10 years). He showed an initial improvement, both in seizure frequency and behavior after this procedure; however seizure frequency returned gradually to baseline persisting improvement in behavior.
- Case 5 received LINAC at the age of 15 (MDE 13 years). He has not shown any change in his clinical manifestations till now.
- Case 6 went through CS at the age of 15 with partial reduction in the size of HH and LINAC 2 years later, without any clinical significant response (MDE 12.14 years).

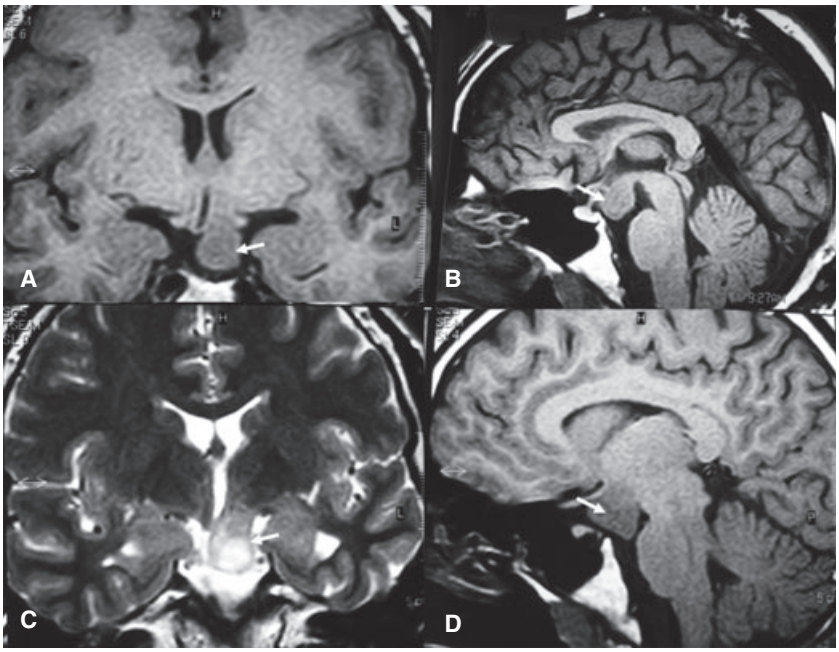

Figure 4. Large and pedunculated hypothalamic hamarthoma corresponding to case 3: (A) in coronal T1-weighted image; (B) coronal T2-weighted image; (C, D) sagittal T1-weighted image.

- Case 7 underwent a GK procedure at the age of 23 (MDE 23 years), without any clinical improvement.
- Case 8 received LINAC at the age of 32 (MDE 24 years) without any clinical changes.

Discussion

HH is a rare central nervous system lesion associated with epilepsy, cognitive difficulties or PP. In our population, onset of seizures was at the mean age of 4.5 years. It occurred as early as the neonatal period (case 7) or as late as adolescence (case 2) and these findings are comparable with other series (1).

GS are considered the most characteristic seizure type observed in these patients and are usually described to be the first manifestation (9–11). In our series, GS was the first seizure type in three of eight patients (37.5%). This kind of seizure was developed later in the course of epilepsy by 87.5% of our population, as one case has never experienced GS. These findings are quite similar to those reported by Nguyen et al. (GS were present in 92% of the patients) (1) and in Mullatti et al. (10) series (84% of the patients). Stereo-EEG recordings of ictal discharges from the hypothalamic lesion, induction of GS by depth electrode stimulation of HH and ictal SPECT hyperperfusion in this area have demonstrated the origin of GS in the hamartoma itself (12). GS of extra hypothalamic lesions exist but are rare (13, 14). Therefore in the presence of GS, the existence of HH should always be excluded.

Multiple additional seizure types (two or more) were observed in seven of eight patients, at the onset of epilepsy or appeared later with the progression of disease. Origin of other seizure types is less clear but, as all seizures types are generally reduced by ablation of the lesion, it can be hypothesized that the hamartoma has a fundamental role in the genesis of the different seizures types, in a direct form or by inducing secondary epileptogenesis (14). Complex partial seizures are similar to those seen in temporal or frontal lobe epilepsies and have led to unsuccessful cortical resections in the past. Sturm et al. (15) reported a group of patients that presented with only an aura described as a 'pressure to laugh' without any other clinical manifestation. The end of the spectrum is a catastrophic epileptic encephalopathy that mimics Lennox Gastaut syndrome. This syndrome was developed by cases 4, 5 and 7. Those patients with EEG generalized or multifocal features showed worst prognosis.

We observed that patients with mild-to-severe mental retardation had complex partial seizures with a frontal semiology, as well as atonic and generalized seizures. Quiske et al. (16) reported, in adult patients with GSHH that were evaluated with a complete neuropsychological assessment, a significant deficit in cognitive functions, especially

in those that involved the frontal lobe. These authors suggest that interictal discharges and ictal seizures with the frontal pattern may be implicated in these findings. Patients with little or no cognitive compromise have been described as having milder seizures and smaller HH (1). However, case 3 who had the larger HH and refractory epilepsy with a high seizure frequency did not exhibit any cognitive difficulties. Although it has been described that pedunculated HH are highly associated with PP (1), this patient also had a pedunculated HH and no signs of PP. This shows that a large variability in the macroscopic characteristics of the lesion exists and a clear correlation between the detailed anatomic features of the HH and the clinical manifestations has not yet been established.

With respect to complementary methods, the diagnosis of HHGS can be determined based on semiology of seizures and MRI. Early MRI exploration of hypothalamic, infundibular and mamillary body areas is mandatory in patients with GS (13). In this context, thin sections should be obtained to ensure a good spatial resolution (17). Video-EEG monitoring was done in 37.5% of our population and its results were not a significant contribution for diagnosis neither for selection of treatment. This is relevant in a country where this study has a low availability and high cost.

With regard to treatment, some authors (13, 18) proposed that the unfavorable evolution can be reversed by means of early surgical or GK ablation, destruction or disconnection of the HH, making this condition a potentially treatable epileptic encephalopathy. Time to reversion depends on the type of seizure and the technique applied. GS and focal seizure seem to cease in the early period after surgery whereas generalized seizures may persist for weeks or months, showing a running down phenomenon. After radiotherapy, reversion usually takes more than 6 months. However there is a lack of evidence, principally from randomized trials, to define the role of each of these therapies. Larger series with longer follow-up periods are needed to compare all these procedures regarding their long-term efficacy and possible side effects (19). All our patients received 'classic' and 'new' drugs in different combinations with some effect in seizure frequency but all of them being refractory. All these patients could benefit with a surgical treatment. However, only five of our eight patients underwent an additional procedure because of difficulties in our country to get access to non-invasive surgical techniques (e.g. GK, endoscopy or LINAC) and the high risk of traditional surgery. On the other hand, regardless of the promising results that have been recently reported in literature, our patients did not have a significant improvement after one or two additional interventions. One possibility of the lack of response could be the long delay between age of seizure onset and the time of the procedure (mean duration of epilepsy was 16 years at the time of the additional procedure). A longer duration of epilepsy could have generated independent secondary epileptogenic foci. The model of epilepsy in HH incorporates the concept of secondary epileptogenesis in neocortex, initially in a reversible manner but potentially becoming permanent in an unknown period of time (20).

This series shows the varied spectrum of this entity and the necessity of longer follow-up series to understand the advantages of each treatment option based on clinical and imaging features. The delay in diagnosis in our patients was probably because they were first seen in non-specialized centers where the knowledge of this syndrome is low. In addition, there was a difficulty in access to treatment options after correct diagnosis which shows the problems in management of this pathology in a developing country.

References

1. Nguyen D, Singh S, Zaatreh M et al. Hypothalamic hamartomas: seven cases and review of the literature. Epilepsy Behav 2003;**4**:246–58.
2. Berkovic SF, Kuzniecky RI, Andermann F. Human epileptogenesis and hypothalamic hamartomas: new lessons from an experiment of nature. Epilepsia 1997;**38**:1–3.
3. Palmini A, Chandler C, Andermann F et al. Resection of the lesion in patients with hypothalamic hamartomas and catastrophic epilepsy. Neurology 2002;**58**:1338–47.
4. Arita K, Ikawa F, Kurisu K et al. The relationship between magnetic resonance imaging findings and clinical manifestations of hypothalamic hamartoma. J Neurosurg 1999;**91**:212–20.
5. Leal AJR, Moreira A, Robalo C, Ribeiro C. Different electroclinical manifestations of the epilepsy associated with hamartomas connecting to the middle or posterior hypothalamus. Epilepsia 2003;**44**:1191–5.
6. Brandberg G, Raininko R, Eeg-Olofsson O. Hypothalamic hamartoma with gelastic seizures in Swedish children and adolescents. Eur J Paediatr Neurol 2004;**8**:35–44.
7. Garcia-Morales I, Marinas A, del Barrio A et al. Hypothalamic hamartoma: clinical characteristics, electroencephalogram and brain magnetic resonance imaging in 10 patients. Neurología 2007;**22**:11–18.
8. Castro LH, Ferreira LK, Teles LR et al. Epilepsy syndromes associated with hypothalamic hamartomas. Seizure 2007;**16**:50–8.
9. Commission on Classification and Terminology of the International League against Epilepsy. Proposal for revised clinical and electroencephalographic classification of epileptic seizures. Epilepsia 1981;**22**:489–501.

10. Mullatti N, Selway R, Nashef L et al. The clinical spectrum of epilepsy in children and adults with hypothalamic hamartoma. Epilepsia 2003;**44**:1310–19.
11. Freeman JL, Harvey AS, Rosenfeld JV, Wrennall JA, Bailey CA, Berkovic SF. Generalized epilepsy in hypothalamic hamartoma. Evolution and postoperative resolution. Neurology 2003;**60**:762–7.
12. Tasch E, Cendes F, Li LM et al. Hypothalamic hamartoma and gelastic epilepsy. A spectroscopic study. Neurology 1998;**51**:1046–50.
13. Striano S, Striano P, Sarappa C, Boccella P. The clinical spectrum and natural history of gelastic epilepsy-hypothalamic hamartoma syndrome. Seizure 2005;**14**:232–9.
14. Kuzniecky R, Guthrie B, Mountz J et al. Intrinsic epileptogenesis of hypothalamic hamartomas in gelastic epilepsy. Ann Neurol 1997;**42**:60–7.
15. Sturm JW, Andermann F, Berkovic SF. Pressure to laugh: an unusual epiletic syndrome associated with small hypothalamic hamartomas. Neurology 2000;**54**:971–3.
16. Quiske A, Frings L, Wagner K, Unterrainer J, Schulze-Bonhage A. Cognitive functions in juvenile and adult patients with gelastic epilepsy due to hypothalamic hamartoma. Epilepsia 2006;**47**:153–8.
17. Cirillo S, Caranci F, Briganti F, DÁmico A, Striano S, Elefante R. Tuber cinereum hamartomas and gelastic epilepsy. Rev Neurorad 1999;**12**:643–52.
18. Berkovic SF, Arzimanoglou A, Kuzniecky R, Harvey AS, Palmini A, Andermann F. Hypothalamic hamartoma and seizures: a treatable epileptic encephalopathy. Epilepsia 2003;**44**:969–73.
19. Schulze-Bonhage A, Homberg V, Triple M et al. Interstitial radiosurgery in the treatment of gelastic epilepsy due to hypothalamic hamartomas. Neurology 2004;**62**: 644–7.
20. Ng Y, Retake HL, Prenger EC et al. Transcallosal resection of hypothalamic hamartoma for intractable epilepsy. Epilepsia 2006;**47**:1192–202.